

Improved visual rehabilitation after cataract surgery

Trifocal lenses : Optics vs Outcomes

TEPLICE/CZ – The AT LISA 839MP (Carl Zeiss Meditec, A.G.) is a multifocal intraocular lens with the inclusion of a third focus for intermediate distance (80 cm) and therefore providing a complete visual rehabilitation after cataract surgery. The main advantage of this IOL compared to previous multifocal IOLs is the significant improvement achieved in the visual acuity at an intermediate distance.



Peter Mojzis

into main zones and phase zones. The diffractive structure has a soft transition of the phase zones between the main zones. The adjusted phase zones were designed to reduce disturbing light phenomena (e. g. scattered light, halos) in order to improve the retinal image quality and visual performance. The controlled number of rings (29 diffractive steps for 0.0 D and 21 steps for +32.0 D IOLs) on the optic surface are intended to reduce the risk of visual disturbances.

The study enrolled a total of 120 eyes of 60 patients. Mean preoperative axial length (AL) and anterior chamber depth (ACD) were 23.50 mm and 3.22 mm, respectively. Mean preoperative keratometry was 43.40 D. The mean value of the IOL power implanted was 21.22 D. In all cases topical anesthesia was applied before the surgical procedure. The microincision with a width of 1.6 mm was placed temporally. After the capsulorhexis and phacoemulsification the trifocal IOL was implanted into the capsular bag through the 1.6 mm wide incision with a single-use Bluemix 180 injector (Carl Zeiss Meditec).

Our study

The study enrolled a total of 120 eyes of 60 patients. Mean preoperative axial length (AL) and anterior chamber depth (ACD) were 23.50 mm and 3.22 mm, respectively. Mean preoperative keratometry was 43.40 D. The mean value of the IOL power implanted was 21.22 D. In all cases topical anesthesia was applied before the surgical procedure. The microincision with a width of 1.6 mm was placed temporally. After the capsulorhexis and phacoemulsification the trifocal IOL was implanted into the capsular bag through the 1.6 mm wide incision with a single-use Bluemix 180 injector (Carl Zeiss Meditec).

Refractive and visual outcomes

Changes in manifest sphere ($p=0.001$) and cylinder ($p=0.003$) were statistically significant at one month postoperatively. During the remaining follow-up (1 to 12 months), non-significant changes in manifest cylinder ($p=0.093$) and small, but significant changes in sphere ($p<0.001$) were observed without any impact on visual performance. The defocus curve remained stable, providing excellent visual acuity at all distances.

Especially the values of visual acuity for intermediate distances were stable, with no statistically significant difference between the visual acuities for defocus levels of -1.0 D (1 m, intermediate distance) and -2.0 D (50 cm, near distance) ($p=0.22$). Statistically significant improvement was

observed at twelve months postoperatively in uncorrected distance visual acuity (UDVA) (0.55 preop vs 0.03 postop logMAR, $p<0.001$), UNVA measured at 33 cm (0.86 vs. 0.23 logMAR, $p<0.001$), and 40 cm (0.86 vs. 0.27 logMAR, $p<0.001$), UIVA measured at 66 cm (0.73 vs. 0.12 logMAR, $p<0.001$) and 80 cm (0.71 vs. 0.11 logMAR, $p<0.001$), DCNVA measured at 33 cm (0.63 vs. 0.21 logMAR, $p<0.001$) and 40 cm (0.63 vs. 0.25 logMAR, $p<0.001$), and DCIVA measured at 66 cm (0.36 vs. 0.11 logMAR, $p<0.001$) and 80 cm (0.33 vs. 0.11 logMAR, $p<0.001$). In contrast, no statistically significant changes were observed at twelve months in CDVA, CNVA and CIVA ($p\geq 0.087$).

One month postoperatively an improvement was observed in all visual parameters ($p\leq 0.03$), except for CNVA measured at 33 cm ($p=0.05$), and CIVA measured at 66 cm ($p=0.24$) and 80 cm ($p=0.25$). From month one to twelve postoperatively small, but statistically significant changes were observed in UDVA ($p<0.001$), CDVA ($p<0.001$), UNVA measured at 33 cm ($p=0.03$) and 40 cm ($p<0.001$), CNVA measured at 33 cm ($p=0.03$), DCNVA measured at 33 cm ($p=0.001$), UIVA measured at 66 cm ($p=0.01$) and 80 cm ($p=0.001$), and DCIVA measured at 66 cm ($p=0.04$). In contrast, changes during this period in CNVA measured at 40 cm ($p=0.05$), DCNVA measured at 40 cm ($p=0.05$), CIVA measured at 66 cm ($p=0.90$) and 80 cm ($p=0.09$), and DCIVA measured at 80 cm ($p=0.12$) were not statistically significant.

Aberrometric outcomes

The aspheric profile of the IOL induces a negative spherical aberration (-0.18 μm) that perfectly compensates for the commonly positive spherical aberration of the cornea, it is therefore leading to postoperative low levels of ocular spherical aberration. In our study the level of internal spherical aberration increased after surgery, resulting in a significant decrease of the level of ocular spherical aberration at six months ($p<0.001$), with no significant changes afterwards ($p=0.306$). Regarding internal aberrations, a significant change was observed in HOA

($p=0.017$) and coma RMS ($p<0.001$) as well as in the Zernike term corresponding to primary spherical aberration at six months postoperatively ($p<0.001$). Between six and twelve months after surgery, a significant change was observed in HOA RMS ($p=0.013$), but not in the levels of coma ($p=0.816$) and spherical aberration ($p=0.410$). These data, especially for coma, confirm the excellent stability of the plate design of the trifocal lens in the capsular bag.

Contrast sensitivity

Contrast sensitivity was slightly, but continuously improving during the follow-up period. Photopic contrast sensitivity was significantly better than that measured under mesopic conditions for all spatial frequencies evalu-

available in spherical powers ranging from -10.0 D to +32.0 D in 0.5 D-increments and in cylindrical powers ranging from +1.0 D to +12.0 D in 0.5 D-increments. The company labelled A-constant for this lens is 118.8.

The preliminary results of 16 eyes implanted with this trifocal toric lens at three months are very promising. The visual acuity was significantly improved for all distances, except corrected-intermediate visual acuity at 66 and 80 cm. No statistically significant changes were observed in the flattest keratometry K1 (42.68 ± 1.98 vs 42.78 ± 1.98 , $p=0.278$), steepest keratometry K2 (44.78 ± 1.75 vs 44.79 ± 1.71 , $p=0.753$), and corneal cylinder (2.03 ± 0.83 vs 1.88 ± 0.81 , $p=0.079$). Regarding the Alps vector analysis,

The lens has a plate haptic design. It is a preloaded IOL with a 6.0 mm biconvex optic and an overall length of 11.0 mm. It is made of a foldable hydrophilic acrylate, with a water content of 25% and a hydrophobic surface. The optic of the IOL consists of a central 4.34 mm trifocal zone and a peripheral bifocal zone in the area from 4.34 to 6.00 mm of diameter. This IOL has a trifocal anterior surface and provides an addition of 3.33 D for near and of 1.66 D for intermediate distance at the IOL level. The IOL does not depend on pupil diameters up to 4.5 mm and provides adequate visual performance under all light conditions. The relative intensity distribution is practically constant up to a diameter of 4.3 mm, with 50% of the relative light intensity for the distance focus, 30% for the near, and 20% for the intermediate focus. For pupils larger than 4.3 mm, the light intensity for the distance focus increases and for the intermediate focus decreases, while the light intensity for the near focus remains constant.

The IOL has a 4-haptic design with an angulation of 0 degrees and a 360-degree square edge to prevent posterior capsule opacification. It is available in spherical powers from 0.00 D to +32.00 D in 0.50-D increments and is implanted with a single-use injector through an incision smaller than 1.8 mm. Its smooth diffractive structure is designed to reduce unwanted diffraction and consequently to increase the optical quality.

Diffractive rings cover the entire optic diameter. The surface is divided

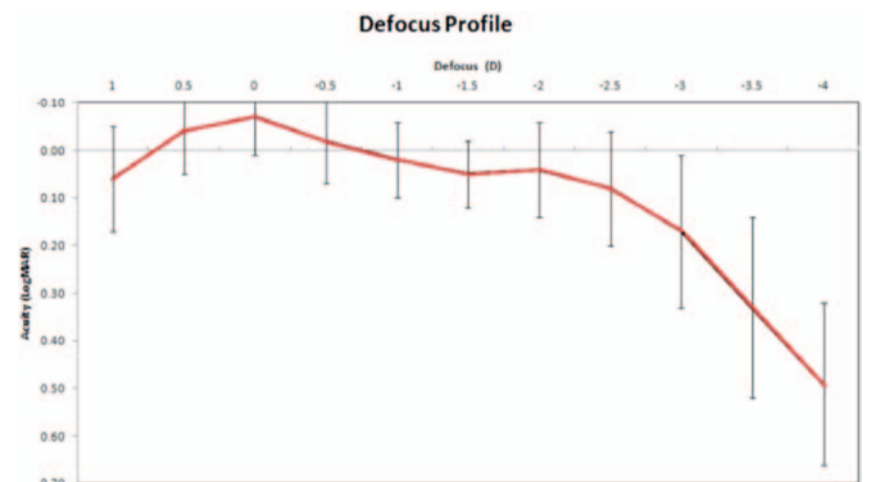


Figure 1 Defocus Curve (120 eyes / three months)

ated ($p<0.001$), but all values were in the normal physiological range at twelve months.

Posterior capsular opacification (PCO)

The IOL has a new square edge which, in combination with the hydrophobic surface, aims at preventing long-term PCO formation. PCO in the 4.3 mm central zone was measured using the EPCO software. Mean EPCO twelve months postoperatively was 0.32 (SD: 0.44, range: 0.00 to 2.11). During the twelve-month follow-up, YAG capsulotomy was only required in four eyes (3.3%) due to the presence of significant levels of posterior capsule fibrosis. However, 15 eyes underwent surgical aspiration of proliferative forms (Elschnigs pearls) (12.5%).

Trifocal toric lens

A toric model of the trifocal lens received the CE approval in 2013. The new AT LISA tri toric 939M/MP (Carl Zeiss Meditec, A.G.) is based on the optical design of the AT LISA tri 839MP and incorporates additionally a bitoric cylinder correction. Bitoricity means that the toric surface is distributed on both the anterior and posterior surface of the IOL. Compared to monotonic designs, bitoric designs provide a larger usable optic with the ability of generating better MTFs for higher cylinders. The multifocal optic is on the front side and the toricity is split on both sides, unlike the AT LISA toric (multifocal on backside, toric on front side). The asphericity of this lens is -0.10 μm . The lens is currently

it revealed that there were very small and no significant differences between the magnitudes of targeted (TIA) (1.76 ± 1.37) and surgically-induced (SIA) (1.78 ± 1.25) astigmatism vectors ($p>0.445$), indicating that the level of astigmatic correction achieved was excellent. The mean magnitude of error (ME) was positive, indicating a minimal trend towards overcorrection of the refractive astigmatism (mean value of 0.15 D at three months), although it was close to 0 and not clinically relevant. The minimal angle of error (AE) was not statistically significant different of 3° , confirming small levels of rotation of the IOL inside the capsular bag. IOL misalignment did not exceed 2° at three months in any case (Figure 2). The mean index of success (IS) (0.22 ± 0.35) was quite low (the lower the value the better the results), and the mean spherical equivalent correction index (SECI) was 1.04 ± 0.79 , being very close to 1.00 that represents the perfect correction of the preoperative refractive error.

Clinical Research Symposium:

Multifocal IOLs: Optics vs Outcomes

Sat, 13.09.2014 13.30 – 15.30
Boulevard B

Author: Peter Mojzis, MD, PhD, FEBO
Medical Director, Premium Clinic Teplice
Chief of the Eye Department, Regional Hospital in Havlickuv Brod, Czech Republic
E-Mail: mojzispeter@hotmail.com

Dr. Mojzis states that he is a speaker and consultant to Carl Zeiss Meditec.

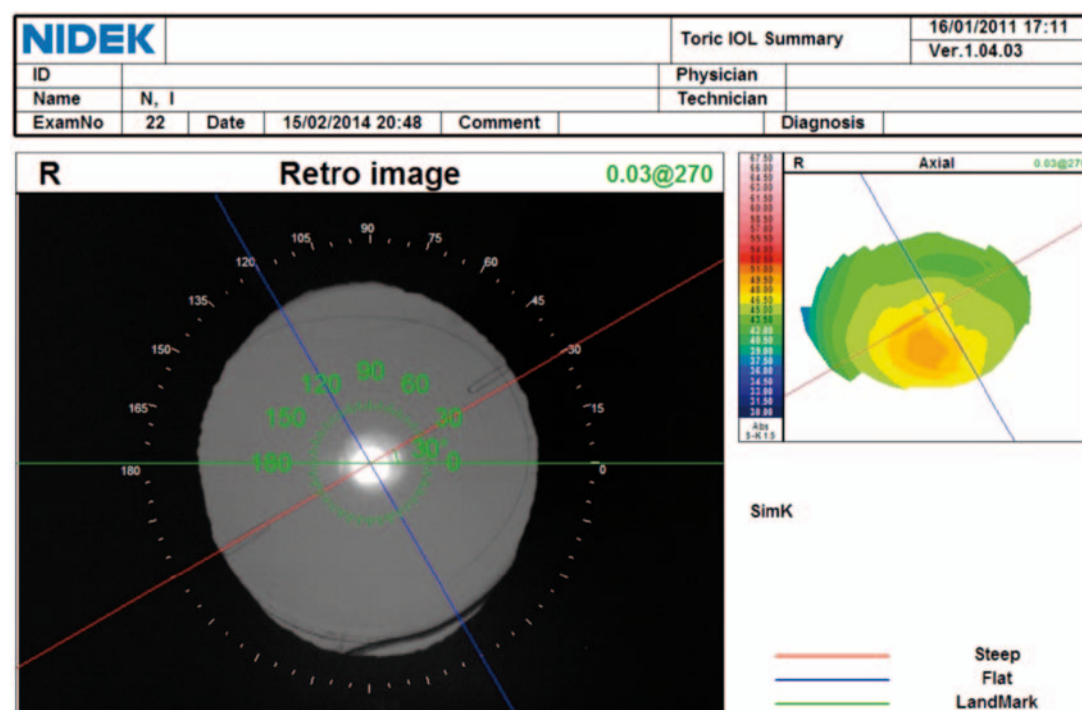


Figure 2 Perfect IOL alignment three months after surgery: The marks on the trifocal toric surface are coincident with steepest meridian (red line)